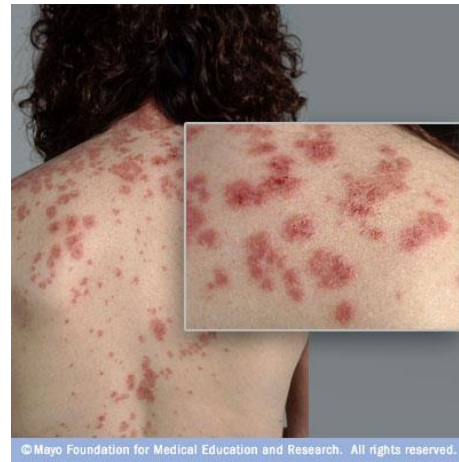
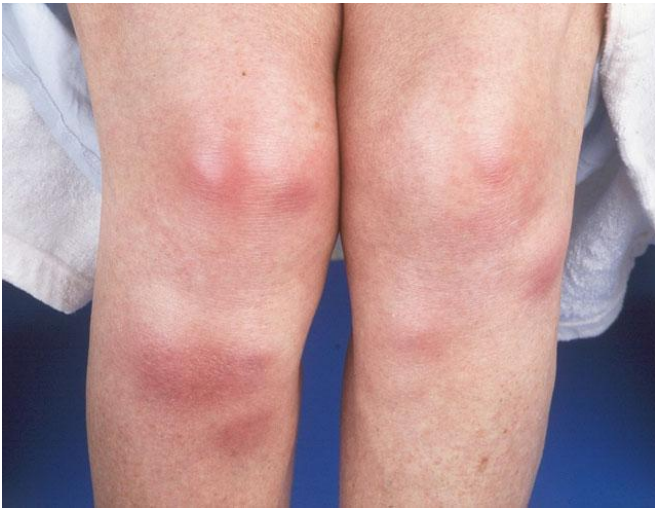
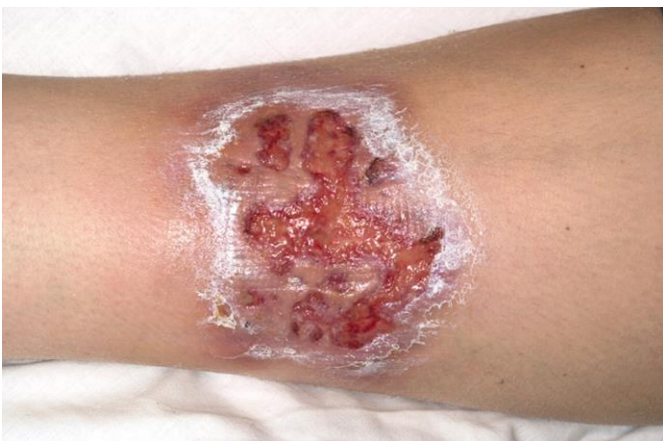

Sweet's Syndrome

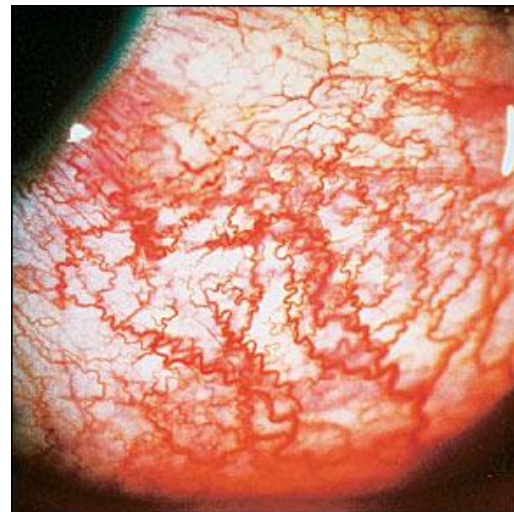<http://www.mayoclinic.com/health/medical/IM00003>

Erythema nodosum: <http://diseasespictures.com/wp-content/uploads/2013/04/Erythema-Nodosum-6.jpg>



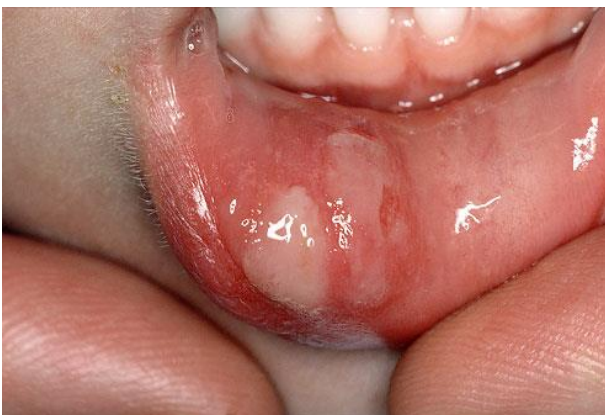Pyoderma gangrenosum

<http://adc.bmj.com/content/90/5/531/F1.large.jpg>



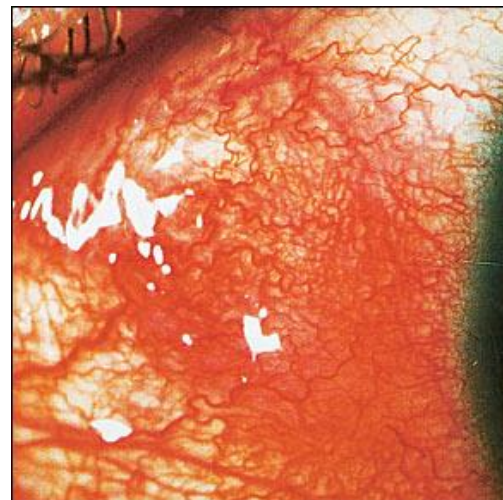
Episcleritis. Engorged episcleral vessels give the eye a bright red appearance. Blanching of the vessels occurs with application of topical phenylephrine 2.5 percent.

<http://www.aafp.org/afp/2002/0915/p991.html>



Oral Aphthous ulcer

<http://www.drpaulose.com/wp-content/uploads/apthous-ulcer.jpg>



<http://www.aafp.org/afp/2002/0915/p991.html>

Scleritis. Engorged scleral vessels do not blanch with application of topical phenylephrine 2.5 percent.